

REVIEW ARTICLE

How to treat cerebral venous and sinus thrombosis

J. M. COUTINHO and J. STAM

Department of Neurology, Academic Medical Centre, University of Amsterdam, the Netherlands

To cite this article: Coutinho JM, Stam J. How to treat cerebral venous and sinus thrombosis. *J Thromb Haemost* 2010; 8: 877–83.

Summary. Cerebral venous and sinus thrombosis (CVT) is a rare form of thrombosis, with many different clinical manifestations. Better imaging techniques have greatly improved the diagnosis, but as a result of the paucity of controlled trials, choosing the optimal treatment for each patient often remains a challenge. Heparin is generally considered the mainstay of treatment, supported by data from a few small trials. More invasive treatment options are available, such as endovascular thrombolysis and – in more severe cases – decompressive hemicraniectomy. Furthermore, CVT is often accompanied by various neurological complications, such as seizures and intracranial hypertension, which require specific treatment. In this review we summarize the available treatment options for CVT and suggest which therapy should be reserved for which patients.

Introduction

Thrombosis of the cerebral venous system, also known as cerebral venous and sinus thrombosis (CVT) or dural sinus thrombosis, is a rare condition, with an estimated annual incidence of 2–4 per million. In comparison, deep venous thrombosis (DVT) of the lower extremity is approximately 250 times as common.

For many years, cerebral angiography was the only technique to definitively diagnose CVT in alive patients [1], but nowadays this invasive procedure is rarely necessary. Although never reliably compared with angiography, magnetic resonance imaging (MRI) combined with MR-venography is now considered the golden standard (Fig. 1A). A good alternative to MRI is computed tomography (CT)-venography, which is considerably faster, more readily available and often produces similar results. Studies that examined the accuracy of CT-venography compared with MRI found a sensitivity and specificity between 75% and 100%, depending on the sinus or vein involved [2,3].

Correspondence: Jan Stam, Department of Neurology (room H2-226), Academic Medical Centre, University of Amsterdam, Meibergdreef 9, 1105 AZ Amsterdam, the Netherlands.

Tel.: +31 20 566 39 43; fax: +31 20 566 39 74.

E-mail: j.stam@amc.uva.nl

In leg-vein thrombosis, the measurement of D-dimer concentration to exclude thrombosis is well established, but in CVT its accuracy is controversial. One study found a high negative predictive value, but this study excluded patients with certain risk factors, such as malignancy and pregnancy, which probably resulted in an overestimation of the specificity [4]. In contrast, a study by Crassard *et al.* [5] reported that 26% of CVT patients with headache as the sole symptom had a normal D-dimer concentration. Several other studies on this subject included only a limited number of patients [6,7]. Until additional data in a larger group of patients become available, routine use of D-dimer measurement to exclude CVT can not be recommended.

Risk factors for CVT are genetic or acquired prothrombotic conditions, systemic inflammatory disease, hematological conditions and many others [8–10]. A local trauma, such as head injury or surgery, may precipitate the thrombosis. Regional infections, especially otitis, were a well-known cause of CVT in the pre-antibiotic era, but are now less frequent. In about 20% of patients no cause or risk factor is identified. In women there is a statistically significant association with oral contraceptive use [11], and CVT is more frequent during pregnancy and in the puerperium. As a result of these gender-specific risk factors CVT is approximately three times more common in women than in men [12]. In children and elderly the genders are equally represented.

CVT usually starts in the large venous sinuses and may extend into the cortical veins. In a minority of cases the thrombosis is limited to the cortical or internal cerebral veins. The clinical symptoms depend on the localization and extension of the thrombus and are highly diverse. When the thrombus is confined to the major sinuses or jugular veins, the main problem is intracranial hypertension, because of diminished venous drainage and a decreased absorption of cerebrospinal fluid. Intracranial hypertension causes headache, often with papilloedema, and sometimes with diplopia as a result of 6th cranial nerve palsy. Severe papilledema can, although rarely, result in blindness. In patients with widespread thrombosis of multiple sinuses, or when the cortical veins become obstructed, additional symptoms often develop. Collateral venous drainage in the brain is limited, and venous obstruction causes increased capillary pressure, cerebral edema and eventually venous infarcts (Fig. 2) [13]. These focal cerebral lesions can result in seizures and neurological signs,

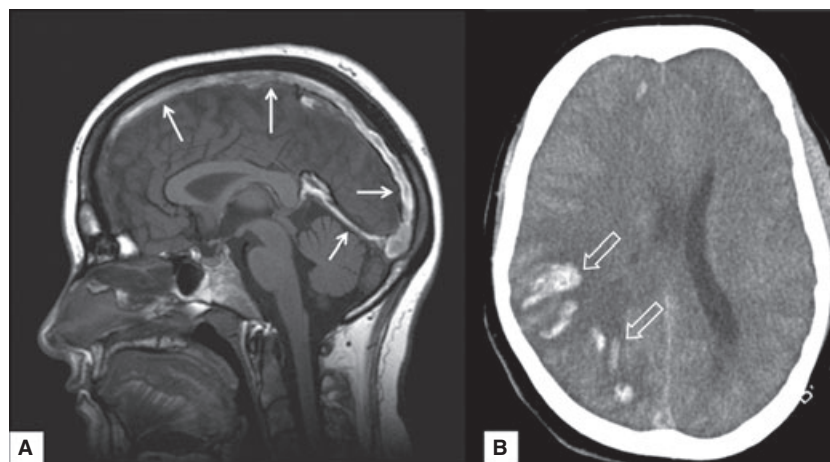


Fig. 1. (A) T1 weighted mid-sagittal magnetic resonance imaging (MRI) showing a thrombus located in the superior sagittal sinus and straight sinus (white arrows). (B) Computed tomography (CT)-scan of a typical venous infarct of the right cerebral hemisphere, with areas of hemorrhage (open white arrows) within a hypointense area of focal edema.

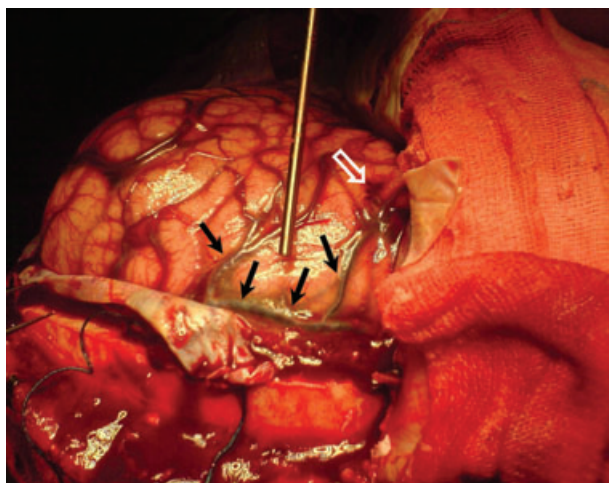


Fig. 2. Posterior view of the right cerebral hemisphere of a 36-year-old patient with cerebral venous and sinus thrombosis (CVT) during decompressive hemicraniectomy. Thrombosis is visible in the multiple cortical veins (black arrows). There is general swelling of the brain as a result of cerebral edema. Small areas with subarachnoid hemorrhage are present around the cortical veins (open white arrow).

such as hemiparesis, aphasia, hemianopia and cognitive disorders. If left untreated, large venous infarcts can be life threatening and death by cerebral herniation may occur within hours in these patients [14].

Venous infarcts develop in approximately half of all CVT patients. A characteristic of these infarcts is their tendency to become hemorrhagic, which occurs in approximately 30–40% (Fig. 1B). The latter feature has raised controversy regarding the treatment of CVT. Heparinization, the obvious treatment for any thrombotic event, was considered dangerous because of the risk of bleeding associated with cerebral venous infarcts. This controversy has been all but resolved in recent years, as will be discussed below.

General measures

Patients with CVT should be admitted and closely monitored in the acute phase, preferably in a stroke unit. This is especially warranted if large venous infarcts or severe intracranial hypertension are present, as these patients can deteriorate rapidly. Also, the risk of seizures, if not already present at baseline, is high in patients with parenchymal brain lesions caused by CVT. Treatable underlying conditions, such as infections, should be identified and treated promptly. To reduce vasogenic cerebral edema, steroids are sometimes administered, but in a post-hoc analysis of a large prospective cohort study, steroids were not shown to be beneficial. Actually, in patients with parenchymal lesions, steroid use was associated with a worse outcome [15].

Anticoagulation

The British gynaecologist Stansfield was one of the first to advocate the use of heparin for the treatment of CVT. In 1941, he described a case of puerperal CVT that responded well to this therapy, and concluded that 'the introduction of heparin gives us an effective weapon to treat what has invariably been a fatal complication of the puerperium, and the clinician's reward for an early diagnosis will be the survival of the patient rather than the sterile pleasure of making an accurate diagnosis and confirming it in the post-mortem room' [16].

While most experts now agree that patients with CVT should receive full anti-coagulation as soon as the diagnosis is made [8,10,17], this policy has been controversial for many years. This may seem counterintuitive to those who treat patients with leg vein thrombosis or pulmonary embolism, conditions in which the use of anti-coagulants has been accepted without reservation. The reason for this controversy was concern about its safety in CVT, because of the high incidence of spontaneous intracerebral hemorrhages. On the other hand, the risk of

withholding anticoagulants is an enlarging thrombus, with the hazard of occluding additional cortical veins and causing more venous infarcts.

Clinical trials to resolve this dilemma are difficult because of the rarity of the disease, and only two small randomized trials that met minimal methodological standards have been performed [18]. The first was a single-center trial that randomized 20 patients to unfractionated heparin or placebo. Heparin dose was adjusted using the activated partial thromboplastin time (aPTT), intended to achieve at least twice the pre-treatment value [19]. All 10 patients in the treatment group had a good outcome at 3 months, whereas in the placebo group three patients died. The second trial randomized 60 patients to subcutaneous low-molecular weight heparin (LMWH) (nadroparin, 90 IU kg⁻¹ twice daily) or placebo [20]. In the nadroparin group, 13% of patients had a poor outcome at 3 months, compared with 21% in the placebo group. In a meta-analysis of the two trials, heparin was associated with an absolute reduction of mortality of 13% (95% confidence interval -27% to 1%, *P* = 0.08) [18]. Although statistically non-significant, for most experts these results confirmed clinical observations that patients put on heparin tend to have better outcomes.

Additional evidence supporting heparin treatment came from the largest prospective cohort study on CVT, the International Study on Cerebral Vein and dural sinus Thrombosis (ISCVT), which included 624 patients, many of whom (39%) had intra-cerebral hemorrhages before treatment [21]. Eighty-three percent of all patients were treated with heparin. The 30-day mortality was only 3.4%, and the final outcomes were better than in many of the older published series.

In spite of these encouraging data, the risk of new or increasing cerebral hemorrhage cannot be discarded as negligible. Although in the two clinical trials no new intracranial hemorrhages developed among the patients treated with heparin [19,20], this finding cannot be generalized confidently as a result of the small number of patients. In the control groups of these trials, however, two patients (out of 40) had a new intracranial hemorrhage, and two others suffered fatal pulmonary embolism, which demonstrates the risk of withholding heparin in these patients.

In patients with deep venous thrombosis of the leg, it is now standard practice to start LMWH instead of unfractionated heparin, as clinical trials have shown that patients treated with LMWH have better outcomes [22]. As a result of a lack of research data, there are no guidelines on which type of heparin to use for CVT. In the ISCVT study, unfractionated heparin was used in approximately three-quarters of patients who received heparin treatment. Advantages of unfractionated heparin are that it may provide a faster therapeutic level of anticoagulation and is easier to antagonize in acute situations, such as the necessity of surgical intervention. We prefer subcutaneous LMWH – in therapeutic dose – because it provides a more stable anticoagulant concentration and does not require dose adjustment based on aPTT measurements.

Endovascular treatment

Many case reports and case series have reported positive results of endovascular thrombolysis for CVT [23,24], but randomized controlled trials have never been performed [25]. An analysis of all case reports up to 2001 showed good clinical outcome (defined as independency in daily activities) in 86% of patients treated with endovascular thrombolysis, a similar outcome as CVT patients treated with heparin [26]. The patients who underwent thrombolysis, however, were in a more severe clinical condition. This seems promising, but due the anecdotal and mostly retrospective evidence, it is impossible to conclude from these data that endovascular treatment is superior to heparin for CVT. An international randomized controlled trial to evaluate the efficacy of endovascular treatment is being prepared and is due to start in 2010. Until the results are available, thrombolysis should be reserved for the very severe cases and for patients who deteriorate despite adequate anticoagulation.

There are several different approaches for endovascular thrombolysis of CVT. The cerebral venous system is accessed by a transjugular or transfemoral approach. A thrombolytic agent, usually urokinase or recombinant tissue plasminogen activator (rt-PA), is then infused into the thrombus (Fig. 3). The dosage of the thrombolytic agent and the duration of thrombolysis are highly variable. Some interventionalists use only bolus injections, whereas others apply local infusions for up to several days [27]. In addition to pharmacological thrombolysis, mechanical techniques such as balloon angioplasty or rheolytic catheters are sometimes used to disrupt and remove clot material [28]. These techniques may reduce the dosage of thrombolytic drugs, and could thus reduce the risk of intracranial hemorrhage. On the other hand, these procedures carry an increased risk of rupturing the vessel wall. A comprehensive review of the different endovascular techniques for CVT is beyond the scope of this paper. For details we refer to several existing reviews on this topic [29,30].

Decompressive hemicraniectomy

Rarely, large hemorrhagic venous infarcts cause displacement of central brain structures (diencephalon and brain stem), a process called cerebral herniation [14]. These patients may initially show signs of third cranial nerve compression (dilated pupil), followed by rapidly progressing coma. If untreated, death from brainstem compression is inevitable. In these situations, emergency decompressive hemicraniectomy can remove the threat of fatal transtentorial herniation. A similar approach can be effective in young patients with malignant middle cerebral artery infarction [31]. In CVT this intervention is applied rarely: in the ISCVT population, only nine patients (1.4%) underwent decompressive hemicraniectomy [21]. We [32] and others [33] have found that prompt hemicraniectomy can be life-saving and result in excellent neurological outcome in these severest cases of CVT. A CT-scan of the brain of a patient successfully treated with decompressive hemicraniectomy is shown in Fig. 4.

Anti-epileptic drugs

Epileptic seizures frequently complicate CVT, occurring in 35–50% of all patients, far more than in arterial strokes [21]. Status epilepticus is less frequent, but potentially life threatening. Predictors for the occurrence of seizures are supratentorial lesions, focal motor deficits and thrombosis of the superior sagittal sinus or cortical veins [34,35]. Most patients suffer from seizures in the acute phase, until 2 weeks from diagnosis, but late seizures do occur. Seizures in the acute phase should be treated promptly with anti-epileptic drugs, preferably by intravenous administration. Because of the high incidence of seizures in patients with CVT, some authors advocate prophylactic anti-epileptic treatment for high-risk patients in

the acute phase [35]. Late seizures usually occur within 6–12 months and mostly in patients who had seizures in the acute phase [36]. We therefore suggest continuing anti-epileptic drugs for 1 year before tapering.

Intracranial hypertension

Increased intracranial pressure is common in CVT. In the acute phase, specific treatment is usually not necessary. Longstanding, severe intracranial hypertension, however, can lead to loss of vision as a result of papilledema. Frequent measurement of vision and evaluation of papilledema is therefore advisable. In case of threatened vision, a lumbar puncture with removal of cerebrospinal fluid can result in immediate improvement of

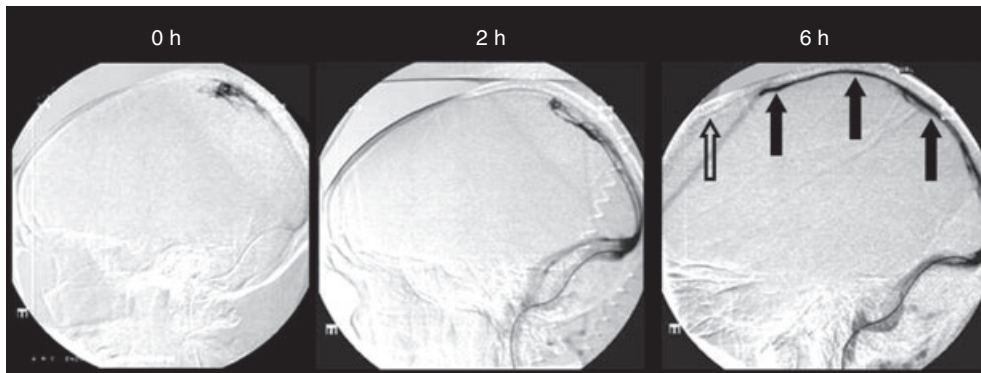


Fig. 3 Endovascular thrombolysis in a 35-year-old patient with thrombosis of the superior sagittal sinus. At the beginning of the procedure, the sinus does not fill with contrast (left). 600 000 IU of urokinase were infused into the superior sagittal sinus, which resulted in partial filling of the proximal part of the sinus after 2 h (middle). An additional infusion of 600 000 IU in 4 h resulted in recanalization of the entire superior sagittal sinus (right, closed arrows), with the exception of the most anterior part (open arrow).

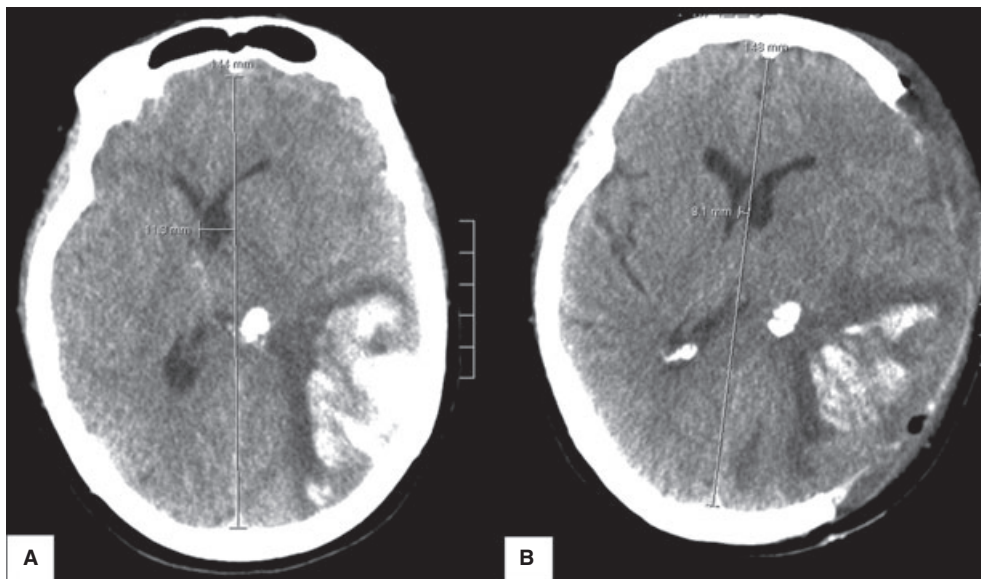


Fig. 4 (A) Computed tomography (CT)-scan of the brain of a patient with cerebral venous and sinus thrombosis (CVT) who became comatose because of transtentorial herniation by a large left-sided parieto-temporal hemorrhagic infarct. There is mass effect and shift of midline structures to the right (midline shift 11 mm). (B) CT scan several hours after hemispherectomy. The midline shift is reduced to 3 mm. After the procedure the patient recovered with mild neurologic sequelae.

symptoms, but contraindications, especially space-occupying mass lesions, should be considered carefully. If multiple lumbar punctures are necessary, a shunting procedure, such as an external lumbar drain, should be considered. A complicating factor with these procedures is that most CVT patients receive anticoagulation, which increases the risk of bleeding complications. In an acute situation with impending visual loss, however, withholding a lumbar puncture is more harmful to a patient than the small risk of bleeding.

Oral acetazolamide or diuretics can effectively reduce intracranial hypertension, but are of limited value in the acute phase. High-dose steroids (e.g. intravenous methylprednisolone 1 g daily for 5 days) have shown to be effective in cases of idiopathic intracranial hypertension [37], but data on its efficacy in CVT are lacking.

Oral anticoagulation

Unless there are evident contraindications, oral anticoagulation with vitamin K antagonists is generally indicated in all CVT patients after the acute phase [38]. If the thrombosis is associated with a transient risk factor, such as an infection or a trauma, a period of 3 months is usually sufficient. In other situations, notably in the case of a recurrent thrombosis, some forms of genetic thrombophilia, an unprovoked thrombosis, a positive lupus anticoagulant or an active malignancy, a longer period of treatment is warranted [38]. Solid data on the optimal duration of treatment in these patients are lacking. Usually a period of 6–12 months is chosen, but occasionally lifelong treatment is indicated in patients with multiple persistent risk factors. It is important to carefully weigh the risks and benefits of treatment in each individual. Target ranges for the international normalized ratio are the same as in deep venous thrombosis of the leg (i.e. 2.0–3.0).

Prognosis and follow-up

The prognosis of CVT was previously considered grave. Mortality rates between 40% and 80% were not uncommon in case series published in the 1950s and 60s [1,39]. This was an overestimation, as CVT could only be diagnosed confidently post-mortem. Modern neuroimaging techniques have led to the identification of many less severe cases, and nowadays the majority of patients with CVT have a favorable prognosis. In the ISCVT study, almost 80% of patients had fully recovered after 6 months of follow-up. Fourteen percent of patients had a poor outcome, half of whom had died. The remaining patients (6%) had a minor disability, but were able to live an independent life [21].

Several small studies investigated recanalization rates after CVT [40]. In the majority of patients, partial or complete recanalization can be demonstrated with MRI. It appears that recanalization predominantly occurs within the first few months, as in two studies in which multiple follow-up MRI's were performed no difference in recanalization rate at 3 months or 1 year was found [41,42]. It is unknown if MRI

visualized recanalization is associated with the probability of recurrence, and no correlation has been found between the degree of recanalization and clinical outcome [41,43]. Therefore, we do not recommend routine use of MRI during follow-up of CVT patients.

Headache is the most common long-lasting symptom after the acute phase, and in a subgroup of patients it can become chronic and excessive [44]. These patients should be carefully evaluated for the presence of chronic intracranial hypertension. Late seizures occur in approximately 10% of patients, usually within the first year [36]. This often has a significant impact on the lives of patients because of the necessity of long-term use of anti-epileptic drugs, driving restrictions and fear of new seizures. Recurrence of CVT is rare and occurs in no more than 3% of patients [40]. Other thrombotic events, mostly deep venous thrombosis of the leg and pulmonary embolism, occur at similar rates. For unknown reasons, this is much lower than reported recurrence rates after deep vein thrombosis [45].

In the follow-up of female patients of childbearing age, counseling regarding the risk of a subsequent pregnancy is often an issue. From the scarce data available, it appears that the risk of a CVT recurrence during pregnancy is very low [46]. As CVT recurrences predominantly occur within the first year, we advise women not to become pregnant within the first year. Thereafter, a former CVT is generally no reason to avoid pregnancy.

Unfortunately, there are no reliable data about antithrombotic prophylaxis during pregnancy in women who suffered CVT. Therefore, we follow general recommendations for venous thromboembolism [47]. Patients who had CVT and a transient risk factor are advised to use LMWH prophylaxis during the post-partum period only (4–6 weeks). In those with CVT and confirmed thrombophilia, or with an apparently spontaneous CVT, prophylaxis throughout pregnancy and puerperium is recommended.

Conclusion

As a result of improved imaging techniques, earlier diagnosis of CVT has become possible. This, combined with now widely accepted early treatment with heparin, has resulted in a much better prognosis for most patients. Still, in a significant minority, CVT remains a severe condition, that may cause lasting neurologic impairment or death. Aggressive treatment, including endovascular thrombolysis and hemicraniectomy, can, however, give excellent results, even in seemingly hopeless cases.

Acknowledgements

We thank Dr B. A. Coert (neurosurgeon) for providing the picture used in Fig. 2, and Dr C. B. L. M. Majoie (neuroradiologist) for his help with the other figures. J. M. Coutinho is supported by 'The Netherlands Organisation for Scientific Research' (NWO), grant number 021.001.045.

Disclosure of Conflict of interests

The authors state that they have no conflict of interest.

References

- Kalbag RM, Woolf AL. Radiology, prognosis, pathology and treatment. In: Kalbag RM, Woolf AL. *Cerebral venous thrombosis*. London: Oxford University Press, 1967; 237–50.
- Ozsvath RR, Casey SO, Lustrin ES, Alberico RA, Hassankhani A, Patel M. Cerebral venography: comparison of CT and MR projection venography. *Am J Roentgenol* 1997; **169**: 1699–707.
- Khandelwal N, Agarwal A, Kochhar R, Bapuraj JR, Singh P, Prabhakar S, Suri S. Comparison of CT venography with MR venography in cerebral sinovenous thrombosis. *Am J Roentgenol* 2006; **187**: 1637–43.
- Kosinski CM, Mull M, Schwarz M, Koch B, Biniek R, Schlafer J, Milkereit E, Willmes K, Schiefer J. Do normal D-dimer levels reliably exclude cerebral sinus thrombosis? *Stroke* 2004; **35**: 2820–5.
- Crassard I, Soria C, Tzourio C, Woimant F, Drouet L, Ducros A, Bousser MG. A negative D-dimer assay does not rule out cerebral venous thrombosis: a series of seventy-three patients. *Stroke* 2005; **36**: 1716–9.
- Misra UK, Kalita J, Bansal V. D-dimer is useful in the diagnosis of cortical venous sinus thrombosis. *Neurol India* 2009; **57**: 50–4.
- Lalivie PH, de Moerloose P, Lovblad K, Sarasin FP, Mermillod B, Sztajzel R. Is measurement of D-dimer useful in the diagnosis of cerebral venous thrombosis? *Neurology* 2003; **61**: 1057–60.
- Stam J. Thrombosis of the cerebral veins and sinuses. *N Engl J Med* 2005; **352**: 1791–8.
- Stam J. Cerebral venous and sinus thrombosis: incidence and causes. *Adv Neurol* 2003; **92**: 225–32.
- Bousser MG, Ferro JM. Cerebral venous thrombosis: an update. *Lancet Neurol* 2007; **6**: 162–70.
- Martinelli I, Sacchi E, Landi G, Taioli E, Duca F, Mannucci PM. High risk of cerebral-vein thrombosis in carriers of a prothrombin-gene mutation and in users of oral contraceptives. *N Engl J Med* 1998; **338**: 1793–7.
- Coutinho JM, Ferro JM, Canhao P, Barinagarrementeria F, Cantu C, Bousser MG, Stam J. Cerebral venous and sinus thrombosis in women. *Stroke* 2009; **40**: 2356–61.
- Fries G, Wallenfang T, Hennen J, Velthaus M, Heimann A, Schild H, Pernecky A, Kempfski O. Occlusion of the pig superior sagittal sinus, bridging and cortical veins: multistep evolution of sinus-vein thrombosis. *J Neurosurg* 1992; **77**: 127–33.
- Canhao P, Ferro JM, Lindgren AG, Bousser MG, Stam J, Barinagarrementeria F. Causes and predictors of death in cerebral venous thrombosis. *Stroke* 2005; **36**: 1720–5.
- Canhao P, Cortesao A, Cabral M, Ferro JM, Stam J, Bousser MG, Barinagarrementeria F. Are steroids useful to treat cerebral venous thrombosis? *Stroke* 2008; **39**: 105–10.
- Stansfield FR. Puerperal cerebral thrombophlebitis treated by heparin. *Br Med J* 1942; **4239**: 436–8.
- Einhauptl K, Bousser MG, de Bruijn SF, Ferro JM, Martinelli I, Masuhr F, Stam J. EFNS guideline on the treatment of cerebral venous and sinus thrombosis. *Eur J Neurol* 2006; **13**: 553–9.
- Stam J, de Bruijn SF, deVeber G. Anticoagulation for cerebral sinus thrombosis. *Cochrane Database Syst Rev* 2002; **4**: CD002005.
- Einhauptl KM, Villringer A, Meister W, Mehraein S, Garner C, Pellkofer M, Haberl RL, Pfister HW, Schmiedek P. Heparin treatment in sinus venous thrombosis. *Lancet* 1991; **338**: 597–600.
- de Bruijn SF, Stam J. Randomized, placebo-controlled trial of anti-coagulant treatment with low-molecular-weight heparin for cerebral sinus thrombosis. *Stroke* 1999; **30**: 484–8.
- Ferro JM, Canhao P, Stam J, Bousser MG, Barinagarrementeria F. Prognosis of cerebral vein and dural sinus thrombosis: results of the International Study on Cerebral Vein and Dural Sinus Thrombosis (ISCVT). *Stroke* 2004; **35**: 664–70.
- van Dongen CJ, van den Belt AG, Prins MH, Lensing AW. Fixed dose subcutaneous low molecular weight heparins versus adjusted dose unfractionated heparin for venous thromboembolism. *Cochrane Database Syst Rev* 2004; **4**: CD001100.
- Stam J, Majoie CB, van Delden OM, van Lienden KP, Reekers JA. Endovascular thrombectomy and thrombolysis for severe cerebral sinus thrombosis: a prospective study. *Stroke* 2008; **39**: 1487–90.
- Wasay M, Bakshi R, Kojan S, Bobustuc G, Dubey N, Unwin DH. Nonrandomized comparison of local urokinase thrombolysis versus systemic heparin anticoagulation for superior sagittal sinus thrombosis. *Stroke* 2001; **32**: 2310–7.
- Ciccone A, Canhao P, Falcao F, Ferro JM, Sterzi R. Thrombolysis for cerebral vein and dural sinus thrombosis. *Cochrane Database Syst Rev* 2004; **1**: CD003693.
- Canhao P, Falcao F, Ferro JM. Thrombolytics for cerebral sinus thrombosis: a systematic review. *Cerebrovasc Dis* 2003; **15**: 159–66.
- Smith TP, Higashida RT, Barnwell SL, Halbach VV, Dowd CF, Fraser KW, et al. Treatment of dural sinus thrombosis by urokinase infusion. *Am J Neuroradiol* 1994; **15**: 801–7.
- Baker MD, Opatowsky MJ, Wilson JA, Glazier SS, Morris PP. Rheolytic catheter and thrombolysis of dural venous sinus thrombosis: a case series. *Neurosurgery* 2001; **48**: 487–93.
- Caso V, Billeci AM, Leys D. Interventional neuroradiology in the treatment of cerebral venous thrombosis. *Front Neurol Neurosci* 2008; **23**: 144–60.
- Renowden S. Cerebral venous thrombosis: local thrombolysis. *J R Soc Med* 2000; **93**: 241–3.
- Vahedi K, Hofmeijer J, Juettler E, Vicaute E, George B, Algra A, Amelink GJ, Schmiedek P, Schwab S, Rothwell PM, Bousser MG, van der Worp HB, Hacke W. Early decompressive surgery in malignant infarction of the middle cerebral artery: a pooled analysis of three randomised controlled trials. *Lancet Neurol* 2007; **6**: 215–22.
- Coutinho JM, Majoie CB, Coert BA, Stam J. Decompressive hemicraniectomy in cerebral sinus thrombosis: consecutive case series and review of the literature. *Stroke* 2009; **40**: 2233–5.
- Stefini R, Latronico N, Cornali C, Rasulo F, Bollati A. Emergent decompressive craniectomy in patients with fixed dilated pupils due to cerebral venous and dural sinus thrombosis: report of three cases. *Neurosurgery* 1999; **45**: 626–9.
- Ferro JM, Canhao P, Bousser MG, Stam J, Barinagarrementeria F. Early seizures in cerebral vein and dural sinus thrombosis: risk factors and role of antiepileptics. *Stroke* 2008; **39**: 1152–8.
- Masuhr F, Busch M, Amberger N, Ortwein H, Weih M, Neumann K, Einhäupl K, Mehraein S. Risk and predictors of early epileptic seizures in acute cerebral venous and sinus thrombosis. *Eur J Neurol* 2006; **13**: 852–6.
- Ferro JM, Correia M, Rosas MJ, Pinto AN, Neves G. Seizures in cerebral vein and dural sinus thrombosis. *Cerebrovasc Dis* 2003; **15**: 78–83.
- Liu GT, Glaser JS, Schatz NJ. High-dose methylprednisolone and acetazolamide for visual loss in pseudotumor cerebri. *Am J Ophthalmol* 1994; **118**: 88–96.
- Kearon C, Kahn SR, Agnelli G, Goldhaber S, Raskob GE, Comerota AJ. Antithrombotic therapy for venous thromboembolic disease: American College of Chest Physicians Evidence-Based Clinical Practice Guidelines (8th Edition). *Chest* 2008; **133**(Suppl): 454S–545S.
- Huhn A. Cerebral venous & sinus thrombosis. *Fortschr Neurol Psychiatr* 1957; **25**: 440–72.
- Dentali F, Gianni M, Crowther MA, Ageno W. Natural history of cerebral vein thrombosis: a systematic review. *Blood* 2006; **108**: 1129–34.
- Stolz E, Trittmacher S, Rahimi A, Gerriets T, Rottger C, Siekmann R, Kaps M. Influence of recanalization on outcome in dural sinus thrombosis: a prospective study. *Stroke* 2004; **35**: 544–7.

- 42 Baumgartner RW, Studer A, Arnold M, Georgiadis D. Recanalisation of cerebral venous thrombosis. *J Neurol Neurosurg Psychiatry* 2003; **74**: 459–61.
- 43 Strupp M, Covi M, Seelos K, Dichgans M, Brandt T. Cerebral venous thrombosis: correlation between recanalization and clinical outcome—a long-term follow-up of 40 patients. *J Neurol* 2002; **249**: 1123–4.
- 44 Koopman K, Uyttenboogaart M, Vroomen PC, van der Meer J, De KJ, Lijckx GJ. Long-term sequelae after cerebral venous thrombosis in functionally independent patients. *J Stroke Cerebrovasc Dis* 2009; **18**: 198–202.
- 45 Hansson PO, Sorbo J, Eriksson H. Recurrent venous thromboembolism after deep vein thrombosis: incidence and risk factors. *Arch Intern Med* 2000; **160**: 769–74.
- 46 Mehraein S, Ortwein H, Busch M, Weih M, Einhaupl K, Masuhr F. Risk of recurrence of cerebral venous and sinus thrombosis during subsequent pregnancy and puerperium. *J Neurol Neurosurg Psychiatry* 2003; **74**: 814–6.
- 47 Bates SM, Greer IA, Pabinger I, Sofaer S, Hirsh J. Venous thromboembolism, thrombophilia, antithrombotic therapy, and pregnancy: American College of Chest Physicians Evidence-Based Clinical Practice Guidelines (8th Edition). *Chest* 2008; **133**(Suppl): 844S–86S.