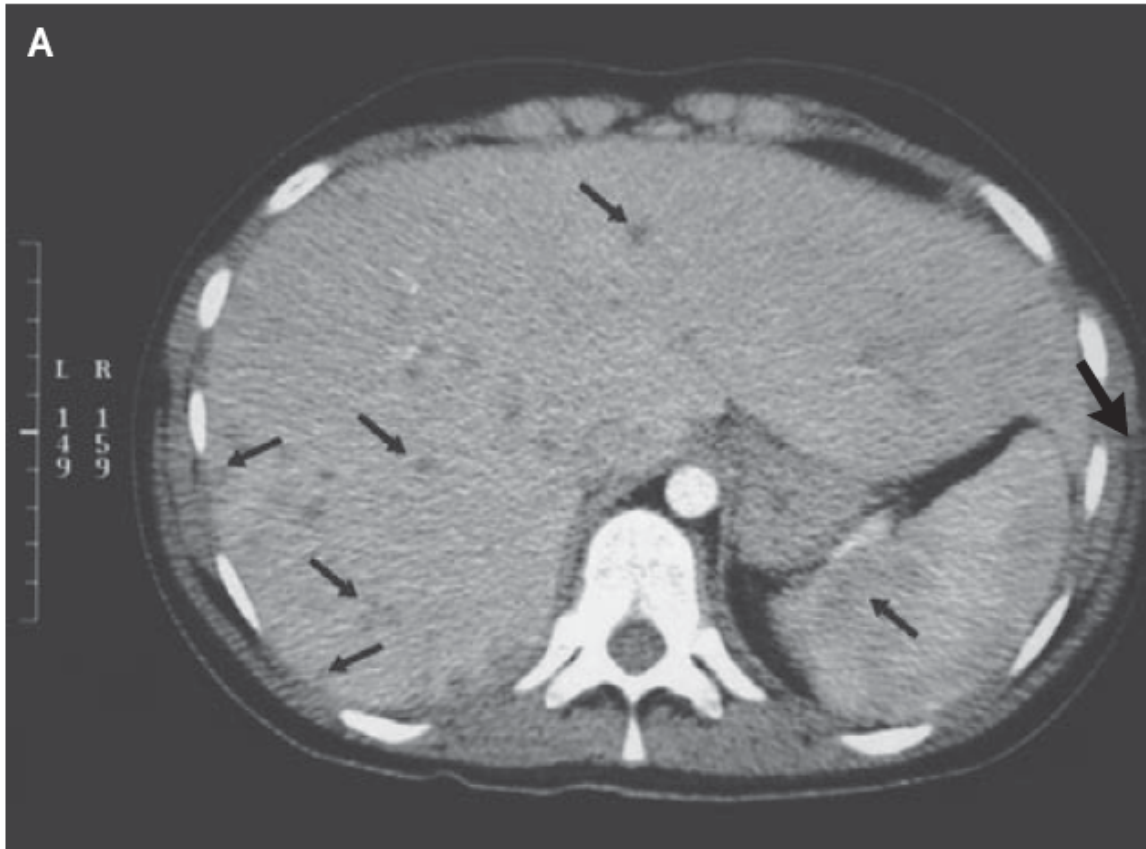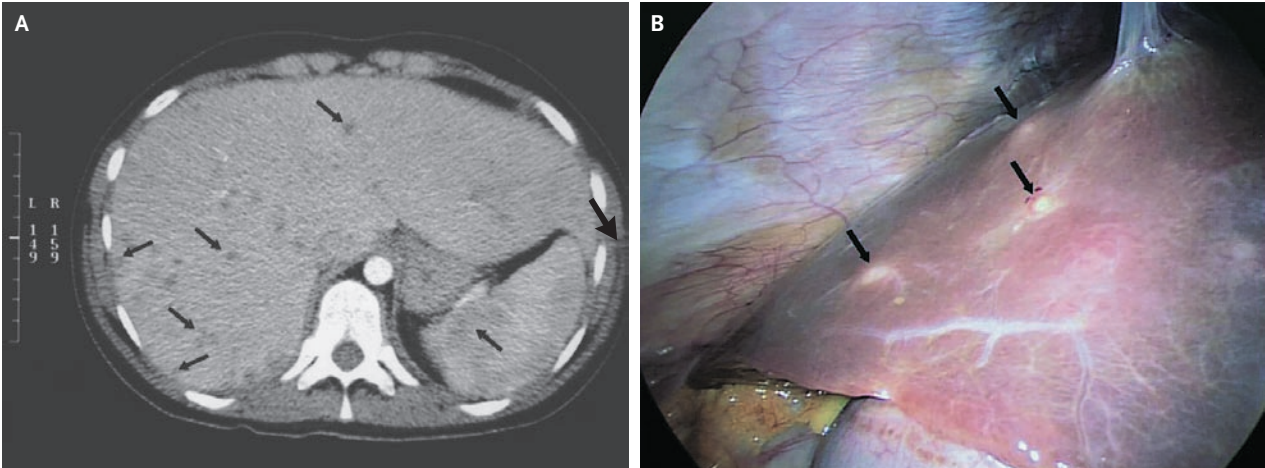




A 19-year-old woman underwent five cycles of chemotherapy for acute myelomonocytic leukemia that had been diagnosed 7 months earlier. During the last cycle of chemotherapy, neutropenia developed, lasting 22 days, during which she had fever that was treated with empirical antibacterial therapy. When the neutrophil count increased, the fever persisted. Her evaluation was notable for a peak temperature of 39.5°C and an increase in the serum alkaline phosphatase level to 335 U per liter. An abdominal computed tomographic (CT) scan showed multiple hypodense lesions in the liver and spleen. What is the likely diagnosis?

Hepatosplenic Candidiasis



Nermin Halkic, M.D.
 Riadh Ksontini, M.D.

University of Lausanne Medical School
 CH-1101 Lausanne, Switzerland
 nermin.halkic@chuv.ch

A 19-YEAR-OLD WOMAN UNDERWENT FIVE CYCLES OF CHEMOTHERAPY FOR acute myelomonocytic leukemia that had been diagnosed 7 months earlier. During the last cycle of chemotherapy, neutropenia developed, lasting 22 days, during which she had fever that was treated with empirical antibacterial therapy. When the neutrophil count increased, the fever persisted. Her evaluation was notable for a peak temperature of 39.5°C and an increase in the serum alkaline phosphatase level to 335 U per liter. An abdominal computed tomographic (CT) scan showed multiple hypodense lesions in the liver and spleen — findings that were consistent with hepatosplenic microabscesses (Panel A, arrows). Since the diagnostic evaluations were unrevealing, diagnostic laparoscopy was performed to obtain biopsy specimens of the hepatic lesions (Panel B, arrows). The causative agent was identified on polymerase-chain-reaction assay as *Candida albicans*. She was treated with fluconazole, and after 1.5 months of therapy, her body temperature was normal. Her serum alkaline phosphatase level had decreased to 185 U per liter, and a follow-up abdominal CT scan showed a decrease in the size and number of lesions in the liver and spleen. Two months later, she underwent successful hematopoietic stem-cell transplantation. Fifteen months afterward, the acute myelomonocytic leukemia recurred, resulting in death from complications of the disease. The diagnosis of hepatosplenic candidiasis is often difficult to make because of a nonspecific clinical presentation. In immunocompromised patients, an unexplained fever that is unresponsive to antibiotic agents should raise the possibility of an invasive fungal infection.

Copyright © 2007 Massachusetts Medical Society.